UDC: 616.724:616-018.2-007.17

O.S. Volovar

National Medical University named after O.O. Bohomolets', Kyiv

Phenotype signs of connective tissue dysplasia in patients with diseases of the temporomandibular joint

The study involved 222 patients with diseases of the temporomandibular joint (TMJ) and phenotypic features of connective tissue (CT) dysplasia have been studied. Incorrect posture (stoop), asthenic type of body structure, curvature of the spine, flat feet, hypermobility of joints (mostly joints of hands and elbow joints) have been discovered, IInd finger length is greater than the IVth finger length, sandal-type gap between the Ist and the IInd fingers of feet, hyper elasticity of skin and damage of its structure (atrophic striae), the presence of hernias, blue sclera, strabismus, astigmatism, as well as brittle nails and nails stratification, low body mass index, hypotension. These features suggest CT functional weakness, reduced elasticity of muscle and ligaments that proves static and dynamic CT failure in patients with TMJ disorders.

Key words: *temporomandibular joint, connective tissue dysplasia, phenotype signs.*

Among the most frequent nosologic forms appearing to a dentist in his practice, a special place belongs to pathology of the temporomandibular joint (TMJ). Causes and mechanism of TMJ disorders usually focus on local factors (abnormal bite, defects, dentition deformities, neuromuscular dysfunctions) (Kupriyanov I.A. et al., 2007). But development of pathological changes in the TMJ and the disease are affected by state of tissue structures that form the joint: bone, cartilage, loose tissue structures (stroma of organs and tissues) and dense (skin, ligaments, tendons, fascia) connective tissue (CT) (Ivasenko P.I. et al, 2001; Kupriyanov I.A. et al., 2007).

CT is a part of almost all organs and systems, along with the blood and lymph it forms the internal environment of the human body. Systematic destruction of CT is due to its prevalence in human body. Phenotype and organ lesions of CT depend on a number of functions, including on its density (Abakumova L.N., 2006).

Damages to dense completed CT causes changes in the skeleton and can be seen in asthenic body structure, dolichostenomelia, arachnodactylia, keel-type or funnel chest, scoliosis, kyphosis and lordosis, syndrome of "straight back", asymmetry in the length of the extremities, flat feet etc. (Golovskoy B.V. s et al., 2002; Belenkiy A.G., 2006; Vorotnikov A.A. et al., 2007).

Congenital or hereditary defects of CT are defined by the most authors as dysplasia. CT dysplasia is a tissue structure anomaly manifesting in reducing certain types of collagen content or violating of their ratio, which reduces the strength of CT in many organs and systems and, consequently, violations of their functions. CT dysplasia can be diagnosed already at the stage of physical examination in the complex evaluation of phenotype (external and visceral) markers (Steinmann B., Royce PM. (Eds), 1993; Golovskoy B.V. et al., 2002; Shylyaev R.R., Shalnova S.N., 2003; Abakumova L.N., 2006).

Mesodermal abnormalities manifest in skeleton changes (deformity of the chest, spine, skull, "gothic palate," slowed growth of the upper and lower jaws, hypermobility of joints), skin and soft tissues (hyper-stretch, thinning, hypoplasia of muscle and adipose tissue), internal organs (heart diseases, valve prolapse, increased diameter of the aorta and pulmonary artery), the organ of vision (severe myopia, aniridia, blue sclera), blood vessels (endothelium disability, increased penetrability and fragility) (Zemtsovskiy E.W., 2000; Belenkiy A.G., 2001; Shylyaev R.R., Shalnova S.N., 2003; Abakumova L.N., 2006).

Clinical manifestations of CT dysplasia are very variable. Manifestations of CT dysplasia of the musculoskeletal system is hypermobility of the joints, flat feet, curvature of the spine, asthenic type of constitution which, according to B.V. Holovsky et al (2002), belong to the copula-articular symptoms of CT dysplasia. Skeletal changes in most cases are related to violation of the cartilage structure, weakness of muscle and bone symptom complex, thus developing hyper luxation in all or several joints, bad posture develops, as well as kyphosis, hyperlordosis, discopathy, scoliosis, flat feet etc. (Zemtsovskiy E.W., 2000; Belenkiy A.G., 2001; Vorotnikov A.A. et al., 2007).

The key etiopathogenetic factor in developing flat feet and curvature of spine, which are quite typical for young people with CT dysplasia, is weakening of muscles and ligaments. This weakness of tendons, muscles and ligaments of the spine leads to incorrect posture (Vorotnikov A.A. et al., 2007).

Weakness of the ligaments causes the syndrome of generalised joint hypermobility (Beighton P. et al., 1989; Zemtsovskiy E.W., 2000), which is a clear symptom of systemic CT inadequacy. According to G.A. Sukhanova (1993), joint hypermobility is found in more than half of patients with CT dysplasia. Women suffer hypermobility of joints more and it is more pronounced than in men. Development of joints hypermobility is associated with changes in the structure and correlation of different types of collagen (Shylyaev R.R., Shalnova S.N. 2003).

Hypermobility syndrome is a combination of hypermobility of joints and any complaints regarding the musculoskeletal system caused by weak ligaments, increase range of motion in one or more joints compared to average values (Belenkiy A.G., 2001).

Due to the weakness of ligaments, legs, feet, bones muscles, static flat feet is observed in 82.1% of patients with CT dysplasia and often has a juvenile form. Static flatfoot is relevant medical and social problem, since feet spring function is damaged in this case, push acceleration is hardly slowed down and is passed around the whole skeleton, which may provoke development of serious illnesses. Longitudinal flat feet has negative effect on lower extremities' biomechanics, leading to an overload of the medial thigh muscles that stabilize shin. According to clinical signs, longitudinal flat feet may look like osteoarthrosis of the knee joint. In addition, longitudinal flat feet can lead to development of osteoarthritis of the knee, so the knee pathology cases in people aged ≤40 in the absence of other available etiologic factors are quite frequent (Belenkiy A.G., 2001; 2006).

An obvious and informative sign of CT is affected ratio and the length of the IInd and the IVth fingers (normally, length of the IInd finger should be more than the IVth one), as well as the Ist and the IInd fingers of foot which form sandal-like gap (Zemtsovskiy E.W., 2000).

Changes in skin CT dysplasia are manifested by thin, vulnerable skin being transparent, by keloid or atrophic scars, striae, freckles, special pigment and de-pigment spots, by big amount of nevi, severity of vascular pattern, subcutaneous venous network. The outward manifestations of CT dysplasia of the eye is blue sclera,

strabismus, astigmatism, myopia of various degrees, retinal detachment, which often happen at displastic processes in the body (Sulimov A.F. et al., 2004; Kadurina T. I., Gorbunova V.N., 2009).

According to I.O. Kupriyanov (2007), pathological TMJ processes can also be signs of CT dysplasia in the young population.

Purpose of this article is to study external phenotypic signs of CT dysplasia in patients with TMJ disorders.

Object and methods of research

The study involved 248 patients, the main group included 222 patients (39 men, 183 women, average age - 26,3 ± 8,0 years) who complained of morning stiffness in the TMJ, intermittent dull aching pain in the TMJ that occurred after chewing solid food, restriction of movement of the lower jaw, crunch in the TMJ. The control group consisted of 26 people (13 men, 13 women, average age - 25,7 ± 6,8 years) without general somatic pathology, with physiological occlusion, without signs of TMJ.

Examination of patients was performed by the standard method for examination of patients with TMJ diseases. Orthopantomography with examination the lower jaw heads, TMJ radiography with open mouth acc. to Parma method, computer or magnetic resonance imaging of TMJ were obligatory.

Examination of patients included a standard set of general clinical examination methods: complaints, history of disease and life, overall examination taking into account symmetry and proportion of the body, posture, body structure type, chest, spine, hands, feet, joints (shoulder, elbow, knee, ankle), skin, sclera, nails, body weight, height.

Body structure was determined quantitatively, calculations of height-weight index (WHI) were performed:

$$WHI = \frac{\text{body weight (kg)}}{\text{height (cm)} \cdot 100\%}$$

Normal WHI is 37-40%. Decrease of this index by => 20% indicates asthenic type of structure, and its increase indicates hypersthenic one. According to E. Krechmer's classification, the type of body structure was defined as:

1) asthenic, i.e. weak (skinny, slim, narrow shoulders, long, narrow and flat chest, tall, elongated face, long thin nose, the lower limbs are long and thin, women are not only thin, but not tall), 2) athletic (developed muscles, strong physique, tall or medium height, broad shoulders, narrow hips, convex facial bones), 3) pyknic that is thick, dense (medium or small height, a lot of adipose tissue, "blurry" body, round head on a short neck, a small broad face, a tendency to obesity), and 4) dysplastic ("shapeless" body structure with different strains - very tall, stoop) (Shchekin G.V., 2001).

Posture was also evaluated (usual person's posture, standing and sitting manner) with sufficient lighting within 2-3 steps from the subject. The following posture was considered correct: head and body are on the same vertical line, shoulders deployed, slightly lowered, blades stick to the back, shoulder girdle deployed, is on one level, physiological curvature of the spine is normal, with the most prominent points of thoracic and sacrococcygeal kyphosis on the same vertical line, depth of cervical, lumbar lordosis is less than 4-6 cm.

Hands examination was performed, taking into account length of the IInd and the IVth fingers, as well as brittle nails and nails stratification. The thumb test was used (laying it across a palm, the thumb's overhanging the lunar edge was marked), as well as wrist test (pinky and thumb easily cover the wrist).

To identify the curvature of the spine and chest deformity, we examined back and spine. In a patient's upright position (hands along the body, heels together) the level of shoulder height, blades camber, gaps between arms and hips were evaluated. All spine was palpated, till the spinous process of the seventh cervical vertebra a thread with a weight to the coccyx was fixed, it was held along the spine and spinal axis was compared to the vertical line created. For defining chest deformation, funnel type cavity availability was studied in the projection of lower third of the chest, its shifting forward, increasing the anteroposterior size and depression of costal cartilages inside, size of intercostal angle was taken into account (90°- cylindrical type, > 90° - conical, < 90° - flat).

The degree of joints hypermobility was assessed by P. Beighton criteria: 1) passive bending of the Vth hand finger is 90° in both directions; 2) passive bending of the Ist hand finger towards forearm at bending at radioulnar joint, and 3) over-bending of both elbow joints by > 10°, 4) over-bending of both knee joints by > 10°, 5) when tilting forward, palms touch the floor at fixed knee joints.

The results were evaluated in 9-point scale: abnormal over-bending of one joint form one side was estimated at 1 point. The maximum points was 9: for the first 4 items - 2 points, for the 5th item - 1 point. 1-2 points were considered normal, slight hypermobility - 3-4 points, moderate mobility - 5-8, severe (generalized) hypermobility of joints - 9 points (Yevtushenko S.K. et al., 2009). Normal indicator at counting of joints hypermobility degree for Europeans (acc. to P. Beighton) makes 0-4 points.

For diagnosis of flatfoot, an examination of right, left foot and patient's shoes was conducted.To study the foot vault and definition of longitudinal flat feet, we used plantomography method for studying a print of a walking part of the feet. To the foot skin Lugol's solution was applied, and in case of intolerance to iodine, we used cream or Vaseline. Potassium iodide and iodine, which are part of Lugol's solution, in contact with cellulose give intense brown staining, a foot remains actually clean; cream or Vaseline were well fixed on paper as indicator materials containing fat. For print, a patient from a seated position put both feet at the same time on a clean sheet of white paper and rose, and then a foot path was contoured and contoured patterns with imprints (plantograms) of iodine solution or grease were received. The arch height and foot length (podometry) were measured and compared, plantograms analysis was performed (Fig.1).

Fig. 1

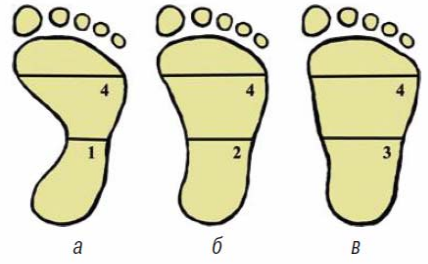

Plantomogram (podogram): а) normal, б) flattened foot vault, в) flat foot vault

To study the transverse flatfoot the following was taken into account: 1) the state of transverse foot vault, 2) a "cushion" in the arch area, 3) the presence of hallux valgus, 4) hammer-like fingers 5) areas of hyperkeratosis at the phalanges and below them, 6) flattened transverse foot vault, 7) pain in the head of metatarsal bones under load (Belenkiy A.G., 2006). For this plantar and dorsum of a foot were examined, their pictures were taken and descriptions were carried out with the definition of a foot deformation degree. Also presence of sandal-type gap between the Ist and the IInd fingers of a foot were taken into account.

Skin condition was evaluated by the following criteria: "thin skin" with visible vascular network, flexibility (elasticity), sagging skin, the presence of atrophic striae not associated with changes in body weight and pregnancy; presence of atrophic or keloid scars, pigment spots ("coffee with milk") or de-pigmentation, severity of subcutaneous venous network, vulnerability, large numbers of nevi, hernias. Skin hyperplasticity was fixed at its painless tension on the hand dorsum, forehead and collarbone area at > 3 cm.

Colour of the sclera was taken into account, as well as presence of capillary grid, irises position, astigmatism, strabismus.

We also determined body height-weight index (WHI), or Quetelet index:

$$WHI = \frac{\text{body weight (kg)}}{\text{height (cm)} \cdot 100\%}$$

Index ≤18.5 kg/m^2 corresponds to a low index (below normal), 18,6-24,9 kg/m^2 – normal, 25-29,9 kg/m^2 - above normal, => 30 kg/m^2 - obesity.

The data were processed on PC with applications Microsoft Excel 2007, Statistica 7.0 and standard version of SPSS 17,0. For sampling, arithmetic mean (M), standard deviation (SD), standard error (SE), version number (n), feature share in % (P) were determined (Halafyan A.A., 2008).

Results and Discussion

Asthenic physique, posture distortion, hypotension, flat feet, sandal-type gap between the first and second fingers of feet, hypermobility of joints, length of the IInd finger that exceeds length of IVth, blue sclera, strabismus, presence of stretch marks, low WHI are external phenotypic signs of CT dysplasia, which were found in the examined patients of the main group.

Asthenic physique as a result of WHI calculations was found in 160 (72.1%) patients, normostenic type of structure - in 40 (18.0%) patients, and hyperstenic - in 22 (9.9%) patients. After examining the patients and determining the type of body structure acc. to E. Krechmer, 175 (78.8%) asthenics, 38 (17.1%) athletics, 5 (2.3%) pyknics, 4 (1.8%) dysplastics were identified. Comparing visual data of body structure type identification with WHI results, we should note that in the group of persons with asthenic type of body structure they almost coincide. Inconsistency of patients' data and WHI results in groups with normostenic and hypersthenic type of body structure may be related to the fact that persons with athletic type body structure can be attributed to both normostenic and to hypersthenic.

Length of the IInd finger exceeded length of the IVth finger in 153 (68.9%) patients of the main group, having asthenic body structure. Thumb test was positive in 179 (80.6%) patients of the main group, the wrist test - in 171 (77.0%) individuals.

Curvature of the spine had varying degrees and localized in respective regions: breast - in 174 (78.4%) patients of the main group, neck and chest - in 4 (1.8%); in chest-lumbar - in 27 (12,2%) patients; neck-chest-lumbar, i.e. S-shaped deformation - in 2 (0.9%) patients, both - females. Thus, generally, curvature of the spine was found in 207 (93.2%) persons, among them 11 (5.3%) patients had pronounced scoliosis (III degree). Only 15 (6.8%) patients had no pathological displacement of the spine (Table). In 1 (0.5%) patient from his history of life surgical correction of the spine on elimination of severe thoracic deformity was discovered, 4 (1.9%) patients had spinal injury, 4 (1.9%) had spine discs displacement. It was found that patients with spinal deformity had osteochondrosis of various locations: all the spine (11 (5.3%) patients), cervical region (33 (15.9%) individuals), cervical-thoracic (10 (4.8%) patients), thoracic (10 (4.8%) patients), lumbar (7 (3.4%) cases), chest-lumbar (5 (2.4%) patients).

Table **Spinal curvature in patients with TMJ**

Spine region suffering curvature of different degrees	Стать		Total n (%)
	men n (%)	women n (%)	
Chest to the left	21 (9,5)	136 (61,3)	157 (70,7)
Chest to the right	3 (1,4)	14 (6,3)	17 (7,7)
Neck-chest	1 (0,5)	3 (1,4)	4 (1,8)
Chest-lumbar	8 (3,6)	19 (8,6)	27 (12,2)
Neck-chest-lumbar (S-type deformation)	0 (0)	2 (0,9)	2 (0,9)
Totally	**33 (14,9)**	**174 (78,4)**	**207 (93,2)**

Body disparity has been found in 4 (1.8%) patients with asthenic type of body structure, in which the body length was greater than length of lower extremities.

Keel-type chest has been found in 3 (1.4%) patients, funnel-type - in 9 (4.1%) patients.

Joints mobility during passive extension of the little finger was > 90° in 171 (77.0%) patients, a positive sign of passive clamp of thumbs to the inside of the forearm - in 167 (75.2%) patients, over-bending at elbow joints > 10° - in 121 (54.5%) patients, in knee joints> 10° - 12 (5.4%) patients, front bending with palms touching the floor with straight legs - in 17 (7.7%) examined. Generalized joints hyper-mobility with the maximum number of points was attributed to 12 (5.4%) patients.

Among patients studied with TMJ disorders, flat feet was found in 200 (90.1%) patients, including 31 (15.5%) - males (Fig. 2).

Fig. 2

Patient S., 18 years old, TMJ arthritis, CT dysplasia, combined flat feet

Among all patients who were diagnosed with flat feet, longitudinal form was found in 8 (4%), transverse - in 15 (7.5%) and combined - in 177 (88.5%) patients. Basic features of longitudinal flatfoot in patients were flattened longitudinal arch, increased length of foot, heel bone was displaced; because a foot was under load of entire surface of the foot bottom - inside of shoe soles and inner edge of heels were worn.

Uncommon foot deformity among persons surveyed was hallux valgus (30 (13.5%) participants), which was formed as a result of varus deviation of the Ist metatarsal bone and valgus deformity in the Ist metatarsal-phalange joint, while the angle between the axis of the Ist toe and the Ist metatarsal bone exceeded 15°. In our patients the cause of hallux valgus was juvenile form, associated with joints hypermobility. The main features of the transverse flat feet was flattened transverse foot arch or its disappearance, bearing of anterior feet on the heads of all five metatarsal bones (normally should be I and V), reducing of a foot length due to deviation of metatarsal bones from the Ist toe, hammer-like deformity of the IIIrd toe. In transverse flatfoot mostly II, III and IV metatarsal bones heads were under load, causing the formation of corns and calluses sometimes expressly painful. Sandal-like gap between the Ist and the IndI toes was found in 135 (60.8%) examined, 21 of them (15.6%) - males.

According to podograms data, the ratio of the widest and narrowest part of the foot was 2:4 in 149 (67.2%) of surveyed individuals, 3:4 in 30 (13.5%) patients (normally should be 1:4).

Patients who had a flattened transverse arch of foot and combined flat feet of III degree (30 persons) were pointing to pain localized in the heads of metatarsal bones, which occurred after prolonged exertion, as well as swelling in the lower extremities, including ankle joints in the evening. Patients with combined flat feet complained of leg fatigue and mild sore feet at the end of the day, or at increase of usual load. Poured pain of the entire foot, rapid fatigue, heaviness in the feet after exercise were attributed to 30 patients with combined flatfoot of the IIIrd level, which may indicate decompensated form of flat feet (Belenkiy A.G., 2006). It should be noted that patients who had longitudinal flat feet complained of intermittent dull pain in knee joints. We should note that such deformation may cause osteoarthritis of knee joints. Pain in the knee joints in the core group of participants can be explained by weakness of ligaments-muscle-joints complex.

27 (12.2%) patients, whose average age was 19,7 ± 3,6 years, walked putting legs with feet turning out, slightly bending legs in knee joints; and their soles under heads of metatarsal bones had calluses (hyperkeratosis). Among them, 15 (55.6%) patients had flat feet of the IIIrd degree, 12 (44.4%) - IInd degree.

Among the control group there were normostenics and athletics. Thoracic scoliosis was detected in 3 (11.5%) cases, flat feet - in 4 (15.4%) cases: longitudinal – in 3 (11.5%), transverse - in 1 (3.8%), roller-type thickening in phalanges areas (I-V) and areas of hyperkeratosis – in 2 (7.7%) patients, hypermobility of joints - in 2 (7.7%) women, the overall points were 5 in 2 women. These persons were doing gymnastics in childhood.

Skin changes were found in 162 (73%) patients, including skin hyper elasticity - in 29 (17.9%) cases; presence of keloids - in 32 (19.8%) patients; severe atrophic white striae across back surface were found only in men (21 (13%) participants) (Fig. 3), and isolated stretching skin atrophy localized in the lower third of the back were found in women (9 (5.6%) patients); in buttocks areas - in 69 (42.6%) patients (68 (42%) women and 1 man); on the outer thighs - in 49 (30.2%) patients, on the back of the thigh, popliteal areas and shins - in 15 (9.3%) people, including 2 men; on the lateral trunk surface in the bottom third - in 46 (28.4%) patients, including 3 (6.5 +3.6%) men; inguinal area (2 (1.2%) men); inner shoulder area (2 (1.2%) men); inner thighs (3 (1 9%) male); breast upper surface - in 6 (3.7%) women, light skin vulnerability - in 7 (4.3%) patients, visible vascular pattern - in 11 (6.8%) cases, spots – in 8 (4.9%) of examined. Atopic dermatitis was attributed to 2 (1.2%) patients.

Fig. 3

Patient G., 21 years old. TMJ arthritis, CT dysplasia, back striae

Hernia of different localization was found in 18 (8.1%) participants: inguinal (12 (5.4%) patients), umbilical (5 (2.3%) patients), white line of the abdomen (1 (0.5 %) women) and abdominal cyst - in 1 (0.5%) women.

Brittle nails were found in 163 (73.4%) patients (17 men, 146 women) of the main group; nails stratification - 3 (1.4%) women; 8 (3,6 ± 1,3%) patients (1 man 7 women) indicated brittle nails during winter-spring period. WHI was under normal value in 43 (19.4%) patients, at the lower limit of normal value (18,5-19 (kg/m^2)) - in 30 (13,5 ± 2,3%) surveyed patients; within normal values - in 132 (59.5%) persons; above normal values - in 10 (4.5%) patients; obesity was diagnosed in 7 (3.2%) surveyed patients. Fragility, nails stratification was found in patients with underweight and asthenic type of body structure. In persons from the control group brittle nails have not been detected, and WHI below normal was found only in 1 (3.9%) woman.

It was found that patients whose WHI values went beyond normal values had incorrect regime and diet, as well as consumption of major macro-, micronutrients, they did not eat enough dairy products, vegetables, fruits, proteins, both of animal and plant origin (meat, fish, nuts, etc.). Their diet was dominated by food with high content of carbohydrates (bread, potatoes), canned food, and smoked food.

Blue sclera was found in 138 (62.2%) patients, blue sclera and marked capillary net - in 69 (31.1%) patients, astigmatism - in 23 (10.4%) patients, displacement of irises - in 1 (0, 5%) of surveyed, coloboma of both eyes - in 1 (0.5%) woman, pupil decentration – in 3 (1.4%) patients, which are signs of CT dysplasia in patients with TMJ disorders.

Among the control group 2 (7.7%) patients had sclera with blue tint, 4 (15.4%) - with severe capillary net.

At posture disorder and scoliosis with different localization the following is characteristic for patients: stooped posture, shoulder girdle asymmetry, reduced circumference of chest, angle of ribs tilt, winged scapula, protruded stomach, muscle hypotonia (Fig.4).

Fig.4

Patient B., 16 years old. TMJ arthropathy, CT dysplasia, asthenic type structure, hypotonia, scoliosis

Most patients studied showed asthenic type of body structure, scoliosis, flat feet, and blue sclera, as evidenced by literature as well (Belenkiy A.G., 2001).

Characteristic feature for patients of the main group was sensitivity to physical stress and susceptibility to frequent injuries (sprains, subluxation of joints, including ankle joints, in history). Patients were encouraged to use orthosis, i.e. inner soles, which type depends on the type of flat feet, with appropriate vault feet modelling, to carefully choose shoes with steady heels 2 cm high for heel bone fixation, with a flexible sole at shank-phalange joints; upper part and front of footwear should be sufficient width and height for comfortable toes position. Knowledge about flat feet symptoms and basics of its treatment are needed for doctors who advise patients with articular syndrome and present hypermobility syndrome.

Thus, when examining patients of young and middle age who have asthenic type of body structure, WHI below the lower limit or at the lower limit, hypermobility of joints, flat feet, striae, skin hyperelasticity, hernia, blue sclera and iris, astigmatism, attention should be paid to possible additional signs of system CT dysplasia: ratio between length of the IInd and the IV fingers, availability of a sandal-like gap between the Ist and the IInd toes, irises coloboma.

In examined patients with TMJ disease (arthropathy, osteoarthritis, and dysplasia) structural body features were measured with anthropometric measurements, which can later be used to identify dysplastic processes in body during preventive examinations and diagnosis. Knowledge of external phenotypic manifestations of CT dysplasia makes it possible to suspect and identify outer manifestations of dysplastic processes in a patient, to provide recommendations for a comprehensive examination, treatment, including physical training: to eliminate stress leading to occurrence of pain, discomfort in the joints; to recommend physical exercises that strengthen muscle tissue with no load on the spine and feet, including swimming, walking. Physical load leads to an increase in CT mass in organs and their strengthening, under mechanical strain CT cells got deformed causing induction of synthesis of proteins and glycosaminoglycans of CT matrix (Kot J.G., 2008).

Also, we corrected diet for the patients (we recommended increased consumption of animal and vegetable protein products, dairy products, etc.), optimized diet, lifestyle and prescribed therapy to strengthen joints, including TMJ (chondroprotectors - chondroitin sulfate, glucosamine, etc.). To treat curvature of spine, flatfoot, patients were sent to the podiatrist for timely correction of this pathology, and with astigmatism, visual disturbances – to an eye specialist.

At that, the more in patients with TMJ disorders we detected external phenotypic signs of CT dysplasia, the more we could expect dysplastic changes in CT of internal organs (Zemtsovskiy E.W., 2000; Shylyaev R.R., Shalnova S.N., 2003; Abakumova L.N., 2006).

Conclusions

The patients of the main group showed external phenotypic signs of CT dysplasia: posture (stoop), asthenic type of body structure, curvature of spine, flat feet, hypermobility of joints (mainly hand and elbow joints), the IInd finger's length is greater than the IVth finger's length, sandal-type gap between the Ist and the IInd toes, skin hyperelasticity and damaging of its structure (atrophic striae), presence of hernias, blue sclera, strabismus, astigmatism, brittle nails and nails stratification, low WHI, muscle hypotonia. These signs evidence of functional CT weakness, reduced elasticity of muscle tissue, of blood and lymph vessels walls, which proves CT failure.

Dysplastic changes of entire skeleton in patients of the main group show significant weakness of copula-muscle-bone complex in etiopathogenesis of pathological changes in the TMJ.

Moreover, given easy detection and a large number of external manifestations of dysplastic changes in the overview, we can already at the stage of physical examination diagnose non-differentiated CT dysplasia.

For patients screening, clinical-anamnestic and functional methods are available. This approach allows us to timely diagnose CT dysplasia and to plan preventive measures. Detection of changes in the musculoskeletal system, skin and sclera in patients with TMJ disorders suggests CT weakness that can lead to joint dysfunction and pathological changes, including TMJ.

Literature

Abakumova L.N. (2006) Clinical forms of connective tissue dysplasia in children. GPMA, St. Petersburg, p. 56.

Belenkiy A.G. (2001) Joints hypermobility syndrome in general practice. Consulting Physician, 5: 76-80.

Belenkiy A.G. (2006) Flatfoot. Polyclinic doctor's reference book .Magazine for post-graduate education of practicing physicians.9 (4): 59-62.

Vorotnikov A.A., Yagoda A.V., Saneeva G.A., Gladkikh N.N. (2007) Complex evaluation of orthopedic status as the necessary component of diagnosis of non-differentiated connective tissue dysplasia. Traumatology and orthopaedics of Russia, 2 (44): 43-47.

Golovskoy B.V., Usoltseva L.V., Hovayeva Y.B., Ivanova N.V. (2002) Features of clinical manifestations of connective tissue dysplasia in persons of active working age. Clinical Medicine, 80 (12): 39-41.

Yevtushenko S.K., Lysovskyy E.V., Yevtushenko O.S. (2009) Connective tissue dysplasia in neurology and paediatrics. Zaslavskyy, Donetsk, p.361

Zemtsovskiy E.V. (2000) Connective tissue heart dysplasia, Polytext-Nord West, St. Petersburg, p. 115

Ivasenko P.I., Yakovlev V.M., Ignatiev Y.T. et al (2001) Disco-plastics dependant pathology of temporomandibular joint. Dentistry, 4: 43-46.

Kadurina T.I., Gorbunova V.N. (2009) Connective tissue dysplasia. Doctors' Guide. ELBY, St. Petersburg., p. 714

Kot Y.G. (2008) Structural and metabolic response of connective tissue to the action of tensile mechanical stress. Author. Thesis. ... Cand. of Med. Science. Kharkiv, p. 20

Kupryyanov I.A. Kupryyanova O.N., Mikheev A.P. et al (2007) Treatment of pain syndrome dysfunction of a temporomandibular joint in patients with connective tissue dysplasia. Rus. Dent.. Magazine, 1: 27-29.

Sulimov A.F., Savchenko R.K., Grigorovich E.Sh. (2004) Connective tissue dysplasia in dentistry and jaw-face surgery. Medical Book, Moscow, p. 134

Sukhanova G.A. (1993) Discovering and correction of haemostasis failure in mesenchymal dysplasia. Author. Thesis. ... Cand. of Med. Science. Barnaul, p.20

Halafyan A.A. (2008) Statistica 6. Data statistical analysis. Binom-Press, Moscow, p. 512

Shylyaev R.R., Shalnova S.N. (2003) Connective tissue dysplasia and its connection with pathology of internal organs in children and adults. Issues of contemporary pediatry, 5 (2): 61-67.

Schekin G.V. (2001) Visual psycho-diagnostics: Recognizing people at their appearance and behaviour. MAUP, Kiev, p.616

Beighton P., Graham R., Bird H. (1989) Hypermobility of joints. 2-nd edition. London, Berlin, Heidelberg et al. Springer-Verlag, 189 p.

Steinmann B., Royce P.M. (Eds) (1993) Connective tissue and its heritable disorders: molecular, genetic and medical aspects. New York, Wiley-Liss, p.351-407.

Phenotype signs of connective tissue dysplasia in patients with diseases of the temporomandibular joint

O.S. Volovar

Summary. *222 patients with diseases of the temporomandibular joint (TMJ) were examined and external phenotype signs of dysplasia of connective tissue (CT) were studied. We revealed malposture (slouch), asthenic type of body structure, curvature of the spine, flat feet, hypermobility of joints (mainly hand, wrist and elbow joints), the II finger was longer than IV, sandal-like fissure between I and II toes, skin hyperelasticity and disorders of its structure (atrophic striae), hernias, blue sclera, strabismus, astigmatism, nails fragility, low body-mass index, hypotonia. These signs indicated a functional weakness of CT, reduced elasticity of muscle and ligaments, which proved the static and dynamic failure of CT in patients with TMJ disorders.*

Key words: *temporomandibular joint, dysplasia of connective tissue, external phenotype signs.*

Address for correspondence:
Volovar Oksana Stepanivna
03680, Kyiv, 1, Zoologichna St.
National Medical University named after O.O. Bohomolets'
E-mail: osvolovar@ukr.net

Received on 01.11.2012

26 червня 2013 року
Переклад даного документу з української мови на англійську виконано в Бюро перекладів «Альфа-Груп».
Адреса: 01601 Україна, Київ, Печерський узвіз, 3, офіс 204.
Контактний номер телефону: (+38 044) 229 6239
Перекладач _____ Михайленко Ганна Володимирівна
Диплом серії ХА № 34472157, виданий Харківським національним університетом імені В.Н. Каразіна 03.07.2008 р.

June 26, 2013
This document is translated from Ukrainian into English in "Alpha-Group", Translation and Marketing Agency.
Address: Office 204, 3 Pecherskyi uzviz, Kyiv, 01601 Ukraine.
Phone No.(+38 044) 229 6239
Translator _____ Ganna Mykhailenko
Diploma Series XA No.34472157, issued by V.N. Karazin Kharkiv National University on July 03, 2008.

Україна * м. Київ * Товариство з обмеженою відповідальністю «БЮРО ПЕРЕКЛАДІВ «АЛЬФА-ГРУП» Ідентифікаційний код 37561340